

Traumatic Diaphragmatic Injury at Gabriel Toure University Hospital, Mali

Amadou Traoré^{1*}, Madiassa Konaté¹, Abdoulaye Diarra², Idrissa Tounkara³, Mohamed Traoré¹, Arouna Doumbia¹, Amadou Bah¹, Boubacar Yoro Sidibé¹, Amadou Maïga¹, Tani Koné¹, Boubacar Karembé⁴, Zakari Saye¹, Koniba Kéita², Yacouba Bouaré¹, Assitan Koné², Ibrahim Diakité¹, Lassana Kanté¹, Bakary Tientigui Dembélé¹, Alhassane Traoré¹, Adégné Togo¹

¹General Surgery Department of Gabriel Touré University Hospital, Bamako, Mali

²Surgery Department of Kati University Hospital, Kati, Mali

³Reference Health Center of Commune II, Bamako, Mali

⁴Reference Health Center of Commune III, Bamako, Mali

Email: *amadoutra242@gmail.com

How to cite this paper: Traoré, A., Konaté, M., Diarra, A., Tounkara, I., Traoré, M., Doumbia, A., Bah, A., Sidibé, B.Y., Maïga, A., Koné, T., Karembé, B., Saye, Z., Kéita, K., Bouaré, Y., Koné, A., Diakité, I., Kanté, L., Dembélé, B.T., Traoré, A. and Togo, A. (2022) Traumatic Diaphragmatic Injury at Gabriel Toure University Hospital, Mali. *Surgical Science*, **13**, 110-118.

<https://doi.org/10.4236/ss.2022.133015>

Received: February 10, 2022

Accepted: March 8, 2022

Published: March 11, 2022

Copyright © 2022 by author(s) and Scientific Research Publishing Inc. This work is licensed under the Creative Commons Attribution International License (CC BY 4.0).

<http://creativecommons.org/licenses/by/4.0/>



Open Access

Abstract

Traumatic diaphragmatic injury (TDI) is rare and is most often the result of a traffic road accident (TRA) or an assault. We initiated this study with the aims of determining the epidemiological, clinical and therapeutic aspects of TDI at Gabriel Toure University Hospital. This was a retrospective study from January 1999 to June 2021 that included all patients who presented a diaphragmatic injury consecutive to abdominal and/or thoracic trauma. In 22 years and 6 months, 46 cases of TDI were collected. They represented 0.17% of hospitalizations, 0.26% of surgical emergencies and 5.5% of thoraco-abdominal traumas. The average age was 31.69 years with a sex ratio of 3.2. Criminal stabbings accounted for 56.5% and TRA for 19.6%. Penetrating injuries accounted for 78.3% of cases. The parietal lesion was thoracic in 21 cases (45.7%), abdominal in 19 cases (41.3%) and thoraco-abdominal in 6 cases (13%). The chest X-ray, performed in 15 patients, showed an intrathoracic gas bubble (4 cases) and hemothorax (6 cases). Diagnosis of diaphragmatic lesion was preoperative in 21.7% (10 cases). The diaphragmatic breach was on the left side in 65.2% (30 cases) and the average size was 3.17 cm. Laparotomy was performed in 89.1%, thoracotomy in 4.4% and thoraco-laparotomy in 6.5% of cases. The surgical procedure consisted of reduction of the herniated viscera in 15.2% (7 cases) and closure of the diaphragmatic breach with non-absorbable sutures in 82.6% (36 cases). Chest tube drainage was performed in 73.9%. The average length of hospital stay was 9.8 days. Mortality was 13.04%. Conclusion: Traumatic diaphragmatic injury is rare but its frequency is increasing in our country. It most often affects the young man victim of assault or TRA. This type of trauma is rarely isolated; you have to think about it in case of any thoraco-abdominal

trauma. The treatment is surgical. The prognosis depends on the severity of the associated lesions.

Keywords

Diaphragmatic Injury, Trauma, Surgery, Gabriel Toure

1. Introduction

Traumatic diaphragmatic injury (TDI) is a rupture of diaphragmatic continuity, often associated with an intrathoracic herniation of abdominal viscera. It is rare with an incidence that varies between 0.8% and 5% of abdominal and/or thoracic trauma [1]. TDIs are most often the result of a traffic road accident (TRA) or an assault by firearm or stab [2] [3].

The preoperative diagnosis of TDIs is a challenge due to the absence of specific symptoms. Computed tomography (CT-scan), which is the imaging of choice, is not always feasible in an emergency. Imaging visualizes the herniated organs but more difficultly the rupture itself. The discovery is therefore often intraoperative (40%) or late (20%) [2].

The treatment of diaphragmatic rupture is surgical and laparotomy is the reference surgical approach. Diaphragmatic wound is repaired with separated non-absorbable sutures and chest tube drain is inserted. Closure of a major diaphragmatic defect may require placement of a non-absorbable mesh [2]. The prognosis depends on the severity of the associated injuries, mortality of trauma victims of TDI is estimated between 8% and 60% [2] [3].

In Mali, a previous study (1999-2015) reported an incidence of 3.7% [4]. However, the present days, characterized by the resurgence of attacks and armed conflicts and the increase in TRA linked to the development of transport means, justified this study, which aims were to determine the epidemiological, clinical and therapeutic aspects of TDI at Gabriel Toure University Hospital.

2. Methods

This was a retrospective study from January 1999 to June 2021, carried out at the general surgery department of Gabriel Toure University Hospital. The study included all patients with diaphragmatic injury following abdominal and/or thoracic trauma who have undergone surgery in the department.

The data studied were: hospital incidence, age, sex, circumstances and mechanisms of trauma, clinical and paraclinical findings, therapeutic aspects and post-operative outcomes. Data were collected from medical records, hospitalization registers and operative reports.

3. Results

In 22 years and 6 months, 46 cases of TDI were collected. They represented

0.17% (46/26,173) of hospitalizations, 0.26% (46/17,404) of surgical emergencies and 5.5% (46/840) of thoraco-abdominal traumas. The average age was 31.69 years with a standard deviation of 13.8 and extremes of 14 and 78 years. Predominant gender was male with 35 cases (76.1%); sex ratio was 3.2.

The main circumstances of injuries were criminal attacks in 33 cases (71.74%) and TRA in 9 cases (19.57%) (**Table 1**). The main mechanism was penetrating stab wounds for 26 patients (56.5%). Mechanisms of injuries are reported in **Table 2**.

The transport means used was non-medical ambulance in 31 cases (67.4%) and improvised means in 15 cases (32.6%). Twenty-six patients (56.5%) were admitted to the emergency room within six hours after the trauma.

The functional signs found were abdominal or thoracic pain in 43 cases (93.5%), dyspnea in 15 cases (32.2%), vomiting in 2 cases (4.3%). The WHO performance index was rated I in 17 cases (37%), II in 26 cases (56.5%) and III in 3 cases (6.5%). Hemodynamic instability was present in 21 patients (45.6%).

On physical examination, wall injury was thoracic in 21 cases (45.7%), abdominal in 19 cases (41.3%); thoraco-abdominal in 6 cases (13%). The other physical signs are reported in **Table 3**.

Abdominal plain X-ray was performed in 7 patients and revealed a pneumoperitoneum in 4 cases. Chest X-ray, performed in 15 patients, revealed an intrathoracic gas bubble (4 cases) and hemothorax (6 cases). CT-scan was performed in 4 patients and revealed herniated abdominal viscera in the thorax in all patients (**Figure 1** and **Figure 2**). Abdominal ultrasound was performed in 11 patients; it showed abdominal fluid effusion in 9 patients. On biology, the hemoglobin level was less than 8g/dL in 19 patients (41.3%).

Table 1. Circumstances of injuries.

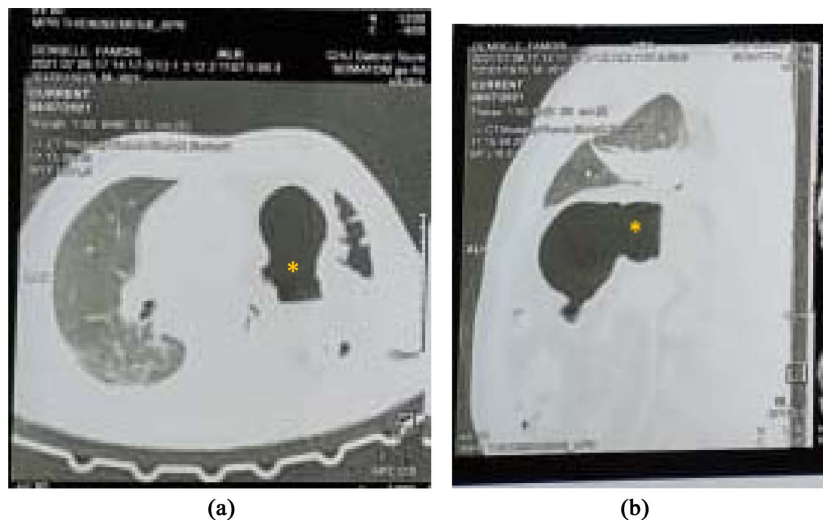
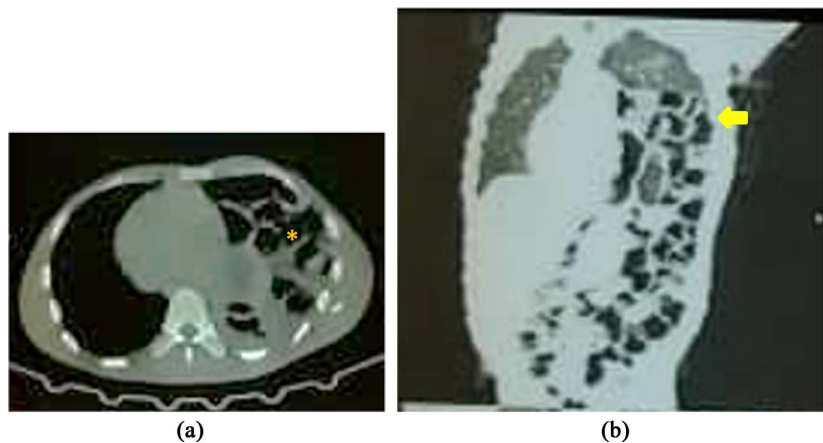
Circumstance of injuries	Effective	Percentage
Attacks	33	71.74
TRA	9	19.57
Fall from height	2	4.35
Landslide	1	2.17
Goring	1	2.17
Total	46	100

Table 2. Mechanisms of TDI.

Mechanisms of injuries	Effective	Percentage
Stab wound	26	56.5
Penetrating Gunshot wound	7	15.2
Other	3	6.6
Blunt	10	21.7

Table 3. Physical examination signs.

Physical signs	Effective	Percentage
Thoracic wall injury	21	45.7
Abdominal wall injury	19	41.3
Thoraco-abdominal wall injury	6	13
Abdominal defense	20	43.5
Abdominal contracture	6	13
Evisceration	13	28.3
Rectal pain	7	15.2
Abolition of breath sounds	7	15.2
Chest dullness	2	4.3

**Figure 1.** CT-scan axial (a) and left sagittal (b) sections showing a large gas bubble with air-fluid level (*) corresponding to a left side TDI with diaphragmatic gastric hernia in a patient at Gabriel Toure University Hospital.**Figure 2.** CT-scan: axial section (a) showing multiple left side intrathoracic air bubbles (*); coronal section (b) showing bowel herniation in the left thorax pushing up the lung (arrow) corresponding to a left side RTI in a patient at Gabriel Toure University Hospital.

The diagnosis of TDI was made preoperatively in 10 patients (21.7%) and intraoperatively in 36 patients (78.3%). The diaphragmatic breach was located on the left side in 30 cases (65.2%) (**Figure 3**) and on the right side in 16 cases (34.8%). The diaphragmatic injury was single in 43 cases (93.5%), double in 3 cases (6.5%). The average size of the injury was 3.17 cm with extremes of 1 cm and 10 cm. TDI was associated with other injuries in 69.6% (**Table 4**). A diaphragmatic hernia was found in 7 cases (15.2%).

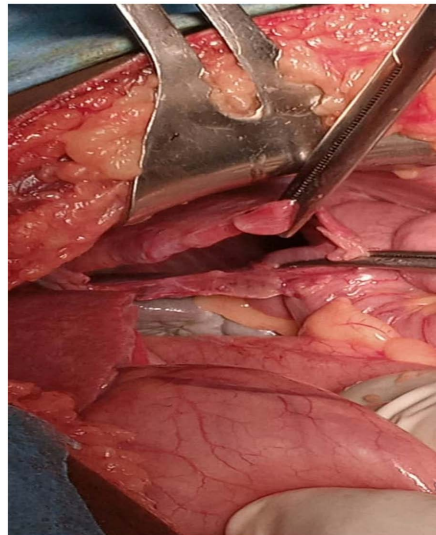

Figure 3. Intraoperative image of left side TDI in a patient at Gabriel Toure University Hospital.

Table 4. Associated lesions and procedures performed.

Associated lesions	Effectif	Procedures	Effectif
Stomach	6	Suture	6
Liver	11	Raphy	9
		Packing	1
		Cholecystectomy	1
Colon	5	Suture	4
		Resection-anastomosis	1
Spleen	4	Splenectomy	3
		Raphy	1
Jejunum	3	Suture	1
		Resection-anastomosis	2
Kidney	2	Any	2
Mesentery	2	Suture	2
Pancreas	1	Any	1
Duodenum	1	Suture	1

Blood transfusion was performed in 14 cases (30.4%). Anti-tetanus prevention was carried out in 31 cases (66.7%). The surgical approach was laparotomy in 41 cases (89.1%), thoracotomy in 2 cases (4.4%) or both in 3 cases (6.5%). Diaphragmatic injuries were repaired with separated non-absorbable sutures in 38 cases (82.6%) and absorbable sutures in 8 cases (17.4%). The chest tube drainage was performed in 34 cases (73.9%) with an average duration of 9 days and extremes of 4 and 15 days. The treatment of associated injuries is reported in **Table 4**.

The average length of hospital stay was 9.8 days with a standard deviation of 5.70 and extremes of 4 and 27 days. The in-hospital outcomes were simple in 37 cases (80.4%). The immediate complications were postoperative peritonitis (1 case), digestive fistula (2 cases), pleurisy (2 cases) and death (4 cases). At one month, the outcomes were simple in 39 cases (92.9%); mortality was 13.04%. All deaths occurred in patient with polytrauma and hemodynamic instability. One patient presented with a recurrence of hemopneumothorax.

4. Discussion

Traumatic diaphragmatic injuries, whether secondary to penetrating or blunt trauma, are rare. They represented 0.8% to 5% of abdominal and/or thoracic traumas in the series of the literature [5-13]. The frequency of TDIs is increasing in our department since it was 3.7% in a previous study (1999-2015) [4] versus 5.5% in our study.

TDI occurs most often in young adults as with all trauma. Moreover, the male gender predominates [6] [8] [10]-[15]. The young man represents the social stratum most exposed to trauma because of his way of life [6].

The circumstances and mechanisms of TDI vary by geographic region. In Europe [1] [14] [15], blunt trauma following TRA is predominant, while in North America, penetrating wounds from gunshot are more frequent [2] [16]. In African series, penetrating stab wounds are the leading mechanism [6] [10] [11] [12]. This predominance was observed in our study (56.5%) and would be linked to the increase in crime and the proliferation of light weapons.

The diagnosis of TDI is difficult and is made in three circumstances: early preoperatively facilitated by imaging, very often intraoperatively during surgical exploration or, more rarely, late a few days to several years after trauma.

Due to its rarity, its non-specific signs and the polytrauma context, the associated lesions occupy the foreground and often conceal the diaphragmatic lesion. For these reasons, the diagnosis is made preoperatively in less than half of patients [2] [6] [10] [11] [12]. This preoperative diagnosis is facilitated by carrying out the abdomino-thoracic CT-scan which is the reference examination and whose sensitivity ranges between 33% and 83%, and specificity between 76% and 100% [1] [12]. However, CT-scan is only performed in a hemodynamically stable or stabilized patient. Chest X-ray, although less effective than CT-scan, is a sensitive diagnostic tool for demonstrating herniation of abdominal viscera in the chest or the ascent of a diaphragmatic dome [8] [10] [13]. MRI is a powerful tool, but its use is limited in emergencies [2].

Most of our cases were diagnosed intraoperatively (78.3%) due to the systematic indication of exploratory surgery in case of penetrating thoraco-abdominal wounds or in the event of hemodynamic instability.

Classically, the left dome of the diaphragm is the most frequently injured in the literature [1] [2] [6] [8] [10] [11] [13]. This predominance of the left side injury was found in our study (65.2%). This can be explained by the protective effect of the liver on the right hemi-diaphragm [5] [6] [8].

The passage of the abdominal viscera into the thorax during RTIs is not constant (15.2% in our study). The most common herniated viscera are the stomach, small and large bowels. In rare cases, the liver and spleen are involved [2] [17]. The herniated viscera in our study were the same as those reported in several series in the literature [6] [10] [11].

Diaphragmatic injuries are rarely isolated; it is most often a polytrauma [2] [5] [6] [9] [13]. In our study, the associated intra-abdominal lesions mainly concerned: the liver, the stomach, the spleen, the gall, the colon. Injuries were also encountered in the pancreas and the kidney. This observation is identical to those reported in the literature [5] [6] [12] [17].

Treatment of TDIs is surgical. Laparotomy is the primary emergency approach; because of the high frequency of associated abdominal injuries and the fact that it allows a complete exploration of the abdominal cavity [2] [7]. However, the type of associated thoracic and/or abdominal injuries most often justifies the choice of approach. Thoracotomy is more indicated in the right locations of the diaphragmatic injury because of the difficulty generated by hepatic interposition [2]. The minimally invasive approach (laparoscopy, thoracoscopy) has a limited indication and is feasible in hemodynamically stable patients, with isolated diaphragmatic injury [2] [8] [16]. In our study, we performed 41 cases of laparotomy (89%); we did not first perform minimally invasive for material reasons.

After reduction of the herniated viscera, the diaphragmatic wound is repaired with separated non-absorbable sutures. Closure of a major diaphragmatic defect may require placement of a non-absorbable mesh [2].

The chest tube drain is inserted but can be removed as soon as lung expansion is obtained in the absence of lung parenchymal injury [2]. A chest tube drain was inserted in 73.9% of our patients for an average duration of 9 days.

Mortality is multifactorial but the prognosis depends above all on the severity of the associated injuries [5] [8] [13]. This mortality would also be higher during contusions compared to penetrating trauma [3] [16]. The mortality in our study (13.04%) is comparable to those reported in the literature (5% to 23%) [3] [4] [6] [8] [10] [18].

The authors admit limitations to the study due to the retrospective nature, in particular the lack of details about some diagnostic and therapeutic aspects.

5. Conclusion

Traumatic diaphragmatic injury is rare, but its frequency is increasing in our country. It most often affects the young man victim of attack or TRA. This type

of trauma is rarely isolated; you have to think about it in case of any thoraco-abdominal trauma. The treatment is surgical. The prognosis depends on the severity of the associated injuries.

Conflicts of Interest

The authors declare no conflicts of interest regarding the publication of this paper.

References

- [1] Corbellini, C., Costa, S., Canini, T., Villa, R. and Avesani, E.C. (2017) Diaphragmatic Rupture: A Single-Institution Experience and Literature Review. *Ulus Travma Acil Cerrahi Derg*, **23**, 421-426. <https://doi.org/10.5505/tjtes.2017.78027>
- [2] Favre, J.P., Cheynel, N., Benoit, L. and Favoulet, P. (2005) Traitement chirurgical des ruptures traumatiques du diaphragme. *EMC—Chirurgie*, **2**, 242-251. <https://doi.org/10.1016/j.emcchi.2005.04.004>
- [3] Fair, K.A., Gordon, N.T., Barbosa, R.R., Rowell, S.E., Watters, J.M. and Schreiber, M.A. (2015) Traumatic Diaphragmatic Injury in the American College of Surgeons National Trauma Data Bank: A New Examination of a Rare Diagnosis. *The American Journal of Surgery*, **209**, 864-869. <https://doi.org/10.1016/j.amjsurg.2014.12.023>
- [4] Dembélé, B.T., Togo, A., Traoré, A., Sidibé, Y., Konaté, M., Traoré, A.A., Bah, A., Koné, T., Tounkara, I., Kanté, L., Diakité, I., Karembé, B., Koné, A., Mangane, M.I. and Diallo, G. (2017) Rupture traumatique du diaphragme. *Revue Africaine de Chirurgie et Spécialités*, **11**, 17-21.
- [5] Giudicelli, R., Lecuyer, T., Velly, J., Grosdidier, G., Heyd, B., D'journo, B., Mantion, G. and Jancovici, R. (2006) Les ruptures diaphragmatiques post traumatiques; Place de la chirurgie mini-invasive. *E-mémoires de l'Académie Nationale de Chirurgie*, **5**, 5-10.
- [6] Choua, O., Moussa Kalli, M., Aboulghassim, O., Sadié Ismael, G., Mantou, B., Kambel, D. and Koumabass, O. (2019) Les traumatismes diaphragmatiques à propos de 26 cas. *RECAC*, **3**, 30-33.
- [7] Chughtai, T., Ali, S., Sharkey, P., Lins, M. and Rizoli, S. (2009) Update on Managing Diaphragmatic Rupture in Blunt Trauma: A Review of 208 Consecutive Cases. *Canadian Journal of Surgery*, **52**, 177-178.
- [8] Tokgöz, S., Akkoca, M., Uçar, Y., Yılmaz, K.B., Sevim, Ö. and Gündoğan, G. (2019) Factors Affecting Mortality in Traumatic Diaphragm Ruptures. *Ulus Travma Acil Cerrahi Derg*, **25**, 567-574. <https://doi.org/10.14744/tjtes.2019.58133>
- [9] Rashid, F., Chakrabarty, M.M., Singh, R. and Iftikhar, S.Y. (2009) A Review on Delayed Presentation of Diaphragmatic Rupture. *World Journal of Emergency Surgery*, **4**, Article No. 32. <https://doi.org/10.1186/1749-7922-4-32>
- [10] Thiam, O., Konate, I., Gueye, M.L., Toure, A.O., Seck, M., Cisse, M., et al. (2016) Traumatic Diaphragmatic Injuries Epidemiological, Diagnostic and Therapeutic Aspects. *SpringerPlus*, **5**, Article No. 1614. <https://doi.org/10.1186/s40064-016-3291-1>
- [11] Camara, A.K., Keita, C.M., Reteno, R.A., Kpoghomou, A.N., Kaba, I., Barry, F.M., Diallo, A.S., Camara, I.A., Magassouba, A.S. and Soumah, M. (2014) Les ruptures diaphragmatiques à l'hôpital national donka: Analyse de 10 cas. *Guinée Médicale*, **55**, 39-45.

- [12] D'Souza, N., Clarke, D. and Laing, G. (2017) Prevalence, Management and Outcome of Traumatic Diaphragm Injuries Managed by the Pietermaritzburg Metropolitan Trauma Service. *The Annals of The Royal College of Surgeons of England*, **99**, 394-401. <https://doi.org/10.1308/rcsann.2017.0029>
- [13] Mahmoud, A.F., Eldin Raeia, M.M., Abo Elmakarem, M.A. (2017) Rupture diaphragm: Early Diagnosis and Management. *Journal of the Egyptian Society of Cardio-Thoracic Surgery*, **25**, 163-170. <https://doi.org/10.1016/j.jescts.2017.05.003>
- [14] Kim, S.H., Cho, J.S., Kim, Y.D., Seok I, H., Song, S., Huh, U., Kim, J.H. and Park, S.J. (2012) Management of Traumatic Diaphragmatic Rupture. *Journal of Trauma and Injury*, **25**, 217-222.
- [15] Lim, B.L., Teo, L.T., Chiu, M.T., Asinas-Tan, M.L. and Seow, E. (2017) Traumatic Diaphragmatic Injuries: A Retrospective Review of a 12-Year Experience at a Tertiary Trauma Center. *Singapore Medical Journal*, **58**, 595-600. <https://doi.org/10.11622/smedj.2016185>
- [16] McDonald, A.A., Robinson, B.R.H., Alarcon, L., Bosarge, P.L., Dorion, H., Haut, E.R., et al. (2018) Evaluation and Management of Traumatic Diaphragmatic Injuries: A Practice Management Guideline from the Eastern Association for the Surgery of Trauma. *Journal of Trauma and Acute Care Surgery*, **85**, 198-207. <https://doi.org/10.1097/TA.0000000000001924>
- [17] Çobanoğlu, U., Kara, V., Yalçınkaya, İ., Er, M., Işık, A.F., Sayır, F. and Mergan, D. (2012) Traumatic Diaphragmatic Ruptures: Diagnostic and Therapeutic Approaches. *Türk Gogus Kalp Damar*, **20**, 85-93. <https://doi.org/10.5606/tgkdc.dergisi.2012.014>
- [18] Hanna, W.C., Ferri, L.E., Fata, P., Razek, T. and Mulder, D.S. (2008) The Current Status of Traumatic Diaphragmatic Injury: Lessons Learned from 105 Patients over 13 Years. *The Annals of Thoracic Surgery*, **85**, 1044-1048. <https://doi.org/10.1016/j.athoracsur.2007.10.084>