

# Transperitoneal Laparoscopic Ureterotomy: A Mini-Invasive Option for Ureteral Stones

Cyril Kamadjou<sup>1,2\*</sup>, Herve Edouard Moby<sup>2</sup>, Annie Kameni Wadeu<sup>1</sup>,  
Achille Mbassi<sup>3</sup>, Bertin Njinou Ngninkeu<sup>1</sup>, Fru Angwafor<sup>4</sup>

<sup>1</sup>Medical and Surgical Center of Urology, Douala, Cameroon

<sup>2</sup>Faculty of Medicine and Pharmaceutical Sciences, Department of Surgery and Specialities, University of Douala, Douala, Cameroon

<sup>3</sup>Higher Medical and Technology Institute, University of Douala, Douala, Cameroon

<sup>4</sup>Coordinator Urology Residency Program, Faculty of Medicine and Biomedical Sciences, University of Yaounde, Yaounde, Cameroon

Email: \*cyrkamadjou@yahoo.fr

**How to cite this paper:** Kamadjou, C., Moby, H.E., Wadeu, A.K., Mbassi, A., Ngninkeu, B.N. and Angwafor, F. (2022) Transperitoneal Laparoscopic Ureterotomy: A Mini-Invasive Option for Ureteral Stones. *Surgical Science*, 13, 135-143. <https://doi.org/10.4236/ss.2022.133018>

**Received:** January 30, 2022

**Accepted:** March 22, 2022

**Published:** March 25, 2022

Copyright © 2022 by author(s) and Scientific Research Publishing Inc.

This work is licensed under the Creative Commons Attribution International License (CC BY 4.0).

<http://creativecommons.org/licenses/by/4.0/>



Open Access

## Abstract

**Background and Objective:** Laparoscopy can be an alternative modality in the management of ureteral stones. We herein present our experience with laparoscopic ureterolithotomy although most ureteral stones are managed using endourologic techniques, open surgery, or shockwave lithotripsy. **Materials and Methods:** This retrospective study was performed from January 2014 to December 2019 on 20 patients with ureteral stones who were treated using transperitoneal laparoscopic access. We collected data on patients' ages, genders, clinical profiles, relevant medical history, sizes of the calculi, localisation of the calculi as confirmed by imaging, and outcome of lithotripsy. Continuous data were presented as mean values and standard deviations (for normally distributed data) and medians with interquartile ranges (for skewed data). Categorical data were presented as frequencies and percentages. **Results:** We included 20 patients (13 males and 7 females) with a mean age of  $40.40 \pm 13.25$  years. The mean stone size was  $18.5 \pm 3.05$  mm and all procedures were completed laparoscopically. The mean operative time was  $96 \pm 22.34$  minutes. The mean estimated blood loss was less than 150 ml, and none of the patients received a blood transfusion. There was no intraoperative complication or postoperative complications, except for leakage of urine in the suture area. The mean hospital stay was  $2.05 \pm 0.69$  days and the double J stent was removed after an average of 20 days post-operatively. The stone-free rate was 100% and after a mean follow-up period of 3 months, there was no stone recurrence. **Conclusion:** Laparoscopic ureterolithotomy is an effective and safe technique in the management of ureteric stones. The benefits of this technique include minimal postoperative morbidity, short postoperative hospitalization, a short convalescence period, and remarkable cosmetic results.

---

## Keywords

Ureteral Calculi, Laparoscopy, Cosmetic Results

---

### 1. Introduction

Different surgical techniques have been established for the management of different types of renal stones, and the choice of a technique depends on the locations and distribution of the stones. These techniques include non-invasive and minimally invasive modalities such as ureteroscopy (URS), extracorporeal shock-wave lithotripsy (ESWL), percutaneous nephrolithotomy (PCNL), laparoscopy, and robotic surgery [1]. Where non-invasive or minimally invasive methods are either unavailable or fail, invasive procedures (including open surgery) can be employed. The American Urological Association (AUA) recommends watchful waiting for patients with uncomplicated ureteral stones  $\leq 10$  mm, URS for patients with mid- or distal ureteral stones who require intervention, and for patients with suspected cystine or uric acid ureteral stones in whom medical expulsive therapy (MET) as a treatment modality for adult patients with ureteral stones fails [2]. In the case of adult patients with renal stones, the AUA recommends ESWL or URS for symptomatic patients with a total non-lower pole renal stone burden of  $<20$  mm, PCNL for symptomatic patients with a total renal stone burden of  $>20$  mm [3]. Laparoscopic ureterotomy (LUT) is an important alternative to percutaneous nephrolithotomy (PCNL) in the management of large ( $\geq 20$  mm) ureteral calculi; however, the latter remains the gold standard [4]. LUT is usually considered in patients who have renal anomalies, are poorly compliant, and have a large single renal-pelvic calculus [5].

LUT could follow a transperitoneal or retroperitoneal approach and is usually performed under general anaesthesia. The transperitoneal approach involves insufflating the abdomen with carbon dioxide and making several small abdominal incisions. In the retroperitoneal approach, a small incision is made in the back and a dissecting balloon is inserted to create a retroperitoneal space. The stone is accessed through an incision in the ureters (ureterotomy). Once the stone is removed, the ureterotomy is usually closed with sutures, with or without a stent placement [6].

LUT, like other surgical procedures, is prone to complications. Potential complications of this technique could either be associated with the removal of the stone or with the closure of the ureterotomy incision [7]. When laparoscopic pyeloplasty with concomitant pyelolithotomy was performed on 15 patients, all of them experienced wall oedema and friability because of the use of irrigation. Also, in a series involving 16 patients who underwent laparoscopic transperitoneal pyelolithotomy as first-line treatment for pelvic stones published by Meria *et al.*, 14 of the patients had urinary leakage as a complication [8] [9]. In this study, we aimed to present our experience with laparoscopic ureterolithotomy in 20 patients at the *Centre medico-chirurgicale d'urologie* in Douala, Cameroon.

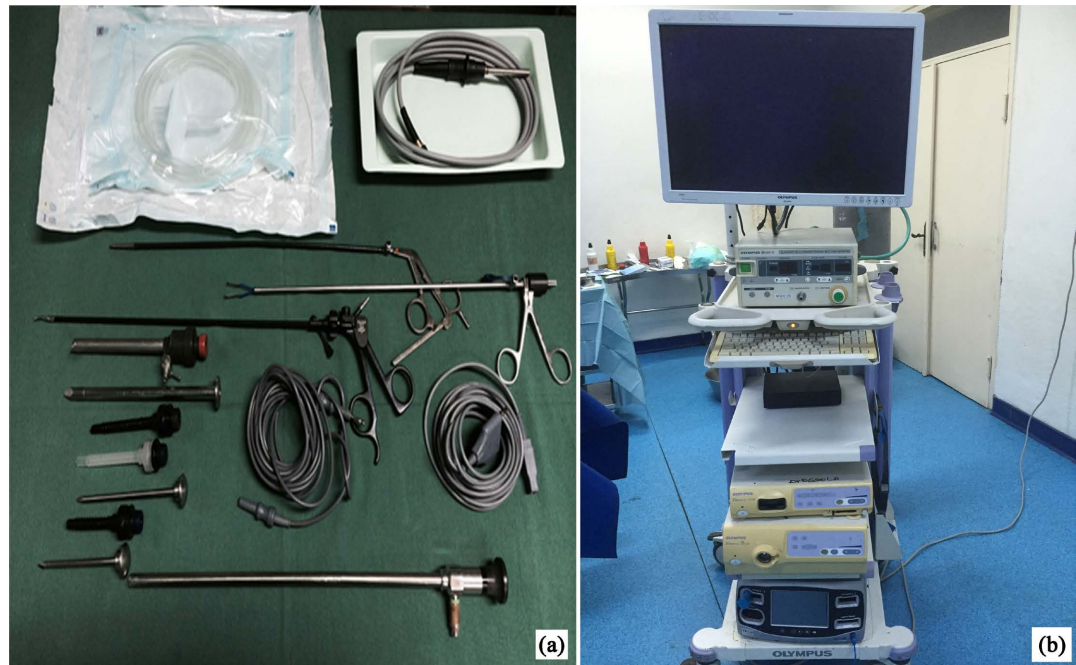
## 2. Methods and Materials

This was a retrospective study carried out over a period of six years (from January 2014 to December 2019) at the *Centre medico-chirurgicale d'urologie*, which is located in Bali, Douala. This is a medical centre that specialises in minimally-invasive surgery and the surgical management of urological pathologies using innovative techniques. The study included 20 patients with large calculi at the ureters who were treated through LUT. The procedure was performed by two surgeons who operated on all 20 patients. The devices used for the laparoscopic procedures are presented in **Figure 1**. All patients underwent abdominopelvic CT before the procedure to localise the stones. All patients benefited from a pre-operative workup, including a full blood count, urea and creatinine, clotting profile, and urine analysis with culture. All patients with confirmed urinary tract infections prior to the intervention were treated as per the results of culture and antibiotic sensitivity profile. A second-generation cephalosporin was administered to all patients without confirmed urinary tract infections as a prophylactic antibiotic. All procedures were performed under general anaesthesia. The patients were placed in the lateral position, and the ureter was accessed transperitoneally. After inserting the abdominal trocars, pneumoperitoneum was achieved, and the kidney and ureter were exposed. The ureter was identified, dissected, and opened. The stones were extracted using rigid laparoscopic forceps. The ureter was sutured following the placement of an antegrade ureteral double J stent. The stones were then removed from the peritoneal cavity. The placement of an intraperitoneal drain concluded the procedure in six cases. Images of the ureteric calculi are shown in **Figure 2**.

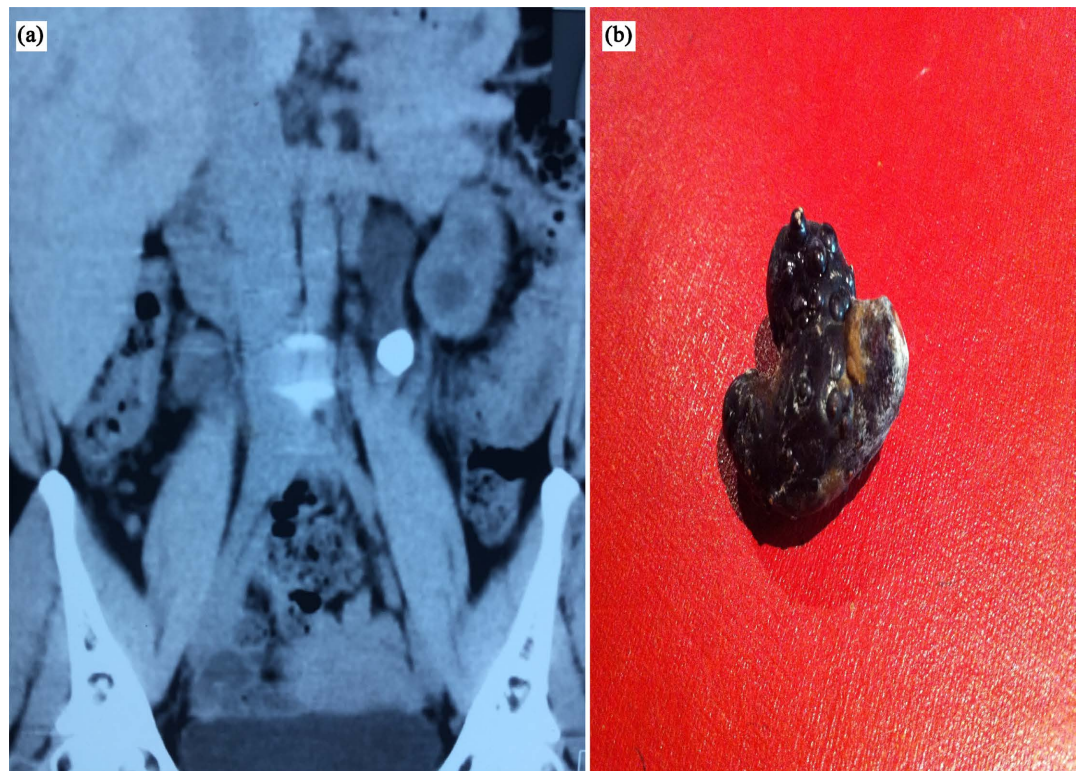
We collected data on patients' ages, genders, clinical profiles, relevant medical history, sizes of the calculi, localisation of the calculi as confirmed by imaging, and outcome of lithotripsy. These data were entered into Microsoft Excel 2016 and exported to Epi info 7 for statistical analysis. Continuous data are presented as mean values and standard deviations (for normally distributed data) and medians with interquartile ranges (for skewed data). On the other hand, categorical data are presented as frequencies and percentages. This study was approved by the institutional review board of the Faculty of Medicine and Pharmaceutical Sciences of the University of Douala and the ethics committee of the Centre medico-chirurgicale d'urologie, Douala, Cameroon. The requirement for informed consent was waived due to the retrospective study design.

## 3. Results

Of the 20 participants we recruited in our study, 7 (35%) were females and 13 (65%) were males. The ages of the participants ranged from 18 years to 65 years, with a median age of  $40.40 \pm 13.25$  years. All 20 patients had kidney stones. These stones were found on the right side of the body in 12 (60%) cases and on the left side of the body in 8 (40%) cases. The stone sizes ranged from 14 mm to 25 mm, with a mean value of  $18.5 \pm 3.05$ . The imaging technique used to locate



**Figure 1.** Laparoscopic devices (a) and Laparoscopic tower (b).



**Figure 2.** CT scan showing an obstructive left ureteral stone (a) and a ureteral stone after laparoscopic extraction (b).

the stones was the anteroposterior CT scan in all the patients.

The clinical presentation of the study participants was acute nephritic colic (ANC) in 16 (80%) cases, acute nephritic colic and sepsis in 2 (10%) cases, and



haematuria in 2 (10%) cases. According to the VAS classification, 13 (65%) participants experienced mild pain, 6 (30%) participants experienced moderate pain, and 1 (5%) participant experienced severe pain. Double J stents were not placed in any of the patients prior to surgery; however, after surgery, drainage using a double J stent was performed in all the patients. The double J stents were removed from the bodies of the patients after a mean duration of  $18.1 \pm 4.34$  days. The duration of the procedure ranged from 60 minutes to 130 minutes, with a mean duration of  $96 \pm 22.34$  minutes. The duration of hospitalization ranged from 1 day to 3 days, with a mean duration of  $2.05 \pm 0.69$ . Percutaneous drainage was not performed in any of the participants. All the participants had no complications after the procedure. The stone-free rate of LUT in this study was 100%.

The estimated blood loss during the procedure ranged from 50 ml to 300 ml, with a median value of 161.75 [100 - 225] ml.

Urinalysis was performed in 2 (10%) of the participants, with the germs identified being *Staphylococcus pyogenes* and *Escherichia coli* in one patient each.

The serum creatinine levels of the study participants ranged from 8 mg/L to 40 mg/L, with a median value of 11.5 [9.5 - 16] mg/L.

There were no complications associated with the procedure in all the patients. The characteristics of the study participants and the procedure are presented in **Table 1**.

**Table 1.** Characteristics of the study participants and the laparoscopic ureterotomy procedure.

VARIABLE	MALE N° (%)	FEMALE N° (%)	TOTAL N° (%)
Number of patients	13 (65)	7 (35)	20 (100)
Mean age $\pm$ SD, years	45.85 $\pm$ 12.25	30.29 $\pm$ 8.50	40.40 $\pm$ 13.25
Mean size of stone (SD), mm	18.85 $\pm$ 3.37	12.86 $\pm$ 2.54	18.5 $\pm$ 3.05
Laterality of the stone			
Right	8 (61.54)	4 (57.14)	12 (60)
Left	5 (38.46)	3 (42.86)	8 (40)
Clinical presentation			
ANC	10 (76.92)	6 (85.71)	16 (80)
ANC and sepsis	1 (7.69)	1 (14.29)	2 (10)
Haematuria	2 (15.38)	0 (0.0)	2 (10)
Intensity of pain			
Mild	6 (46.15)	7 (100)	13 (65)
Moderate	6 (46.15)	0 (0.0)	6 (30)
Severe	1 (7.70)	0 (0.0)	1 (5)
Urinalysis			
Yes	2 (15.38)	0 (0.0)	2 (10)
No	11 (84.62)	0 (0.0)	18 (90)
Creatinine level in mg/L, median [IQR]	13 [9 - 15]	10 [10 - 20]	11.5 [9.5 - 16]

**Continued**

Number of clients with double J stent post-op	13 (100)	7 (100)	20 (100)
Mean number of days double J stents were left in situ	18.31 ± 5.25	17.71 ± 2.06	18.1 ± 4.34
Duration of hospitalization in days, mean ± S.D.	1.92 ± 0.64	2.29 ± 0.76	2.05 ± 0.69
Duration of LUR procedure in minutes, mean ± S.D.	98.08 ± 24.20	92.14 ± 19.55	96 ± 22.34
Estimated blood loss in ml, median [IQR]	155.77 [100 - 220]	172.86 [100 - 225]	161.75 [100 - 225]

**4. Discussion**

In this study, we recruited 20 participants who underwent LUT. The median age of our study participants was  $40.40 \pm 13.25$  39.5 years, which is similar to the mean ages of 38.5 years and 37.9 years reported by Tiwari *et al.* [10] and Sahin *et al.* [11], respectively. These similarities are probably due to the similarities in the sizes of the study samples used. There were 13 (65%) men and 7 (35%) women among the 20 participants. Similar results were reported by Bokka and Jain in 2019 [12]. This is in line with the general finding that calculi are more common in men than in women [13].

Complete stone clearance was observed in all participants in our study. Şahin *et al.* [14] reported a similar stone-free rate of 99% despite recruiting 213 participants. Sahin *et al.* [11] also reported similar results; however, although their study sample (19 participants) and the demographic profile of their study participants (14 men and 5 women; mean age: 37.9 years) were similar to ours, they performed laparoscopic retroperitoneal ureterolithotomy with concomitant pyelolithotomy using flexible cystoscope through the ureterotomy site, whereas we performed just laparoscopic ureterotomy. In addition, they used holmium laser lithotripsy in 4 cases before achieving complete stone clearance in all their participants. In 2008, Shrestha *et al.* reported a 100% stone clearance rate three months after ureteroscopic pneumatic lithotripsy in 92 consecutive patients who had 95 ureteric stones from 2005 to 2006. However, although the stone clearance rate was 100%, the rate of complications was 51% [15], which is different from the 0% complication rate we found in our study. The difference in the rate of complications could be due to the differences in the sizes of the study samples and the fact that pneumatic lithotripsy is a technique that has been associated with a relatively higher rate of complications and a relatively longer duration of the procedure in previous studies [16]. The mean hospital stay in our study was  $2.05 \pm 0.69$  days, which is different from the  $2.6 \pm 1.4$  days reported by Al Sayyad in 2012 [17]. This difference could be because although his technique was similar, Al Sayyad recruited fewer participants (12 patients) in his study. His participants were also older (mean age:  $52.9 \pm 12$  years), and his patients had larger stones ( $\geq 20$  mm). The mean hospital stay in our study was also shorter than that reported by Bayar *et al.* who performed laparoscopic ureterolithotomy on 20 patients in 2014 [18]. The mean duration of the intervention in our study was  $96 \pm 22.34$

minutes. This is higher than the 86.5 minutes reported by Sahin *et al.* in 2016 [11] but lower than the  $107 \pm 49.5$  minutes reported by Al Sayyad in 2012 [17]. Al Sayyad's interventions probably lasted longer because he was working on older patients who had larger stones. However, the mean duration of the intervention in our study was also lower than the  $145 \pm 42$  minutes reported by El-Feel *et al.* in 2007 [19] although they used a similar technique on a similar number (25) of patients of similar age (mean age:  $39.8 \pm 17.5$  years). We have to admit that the duration of the surgery is also in relation to the experience of the surgeon.

The estimated blood loss in our study was higher than those reported by El-Feel *et al.* [19] and Şahin *et al.* [14]. This can be explained by the fact that in our study, the dissection was rendered difficult by the presence of many surgical adhesions due to inflammation caused by long-term and big calculi and can explain our results.

However, our study had a few limitations. First, our sample size was small. This is mainly because patients in our context still consider laparoscopic procedures to be experimental; as such, they tend to opt for open surgery and shun laparoscopic procedures. Second, the retrospective study design means that there was recall bias. In spite of its limitations, this study on laparoscopic ureterolithotomy is the first of its kind in our context. We believe that with the findings of our study, the efficacy and safety of this technique will be better appreciated and it will attract the interest of policymakers, physicians, and patients, leading to its integration as part of routine healthcare in our context.

## 5. Conclusion

Laparoscopic ureterolithotomy is an effective and safe technique in the management of ureteric stones. The benefits of this technique include minimal post-operative morbidity, short postoperative hospitalization, a short convalescence period, and remarkable cosmetic results.

## Acknowledgments

The authors thank Health Search Association for their contribution to this work.

## Conflicts of Interest

The authors declare no conflicts of interest regarding the publication of this paper.

## References

- [1] Fontenelle, L.F. and Sarti, T.D. (2019) Kidney Stones: Treatment and Prevention. *American Family Physician*, **99**, 490-496.
- [2] Pearle, M.S., Goldfarb, D.S., Assimos, D.G., Curhan, G., Denu-Ciocca, C.J., Matlaga, B.R., *et al.* (2014) Medical Management of Kidney Stones: AUA Guideline. *The Journal of Urology*, **192**, 316-324. <https://doi.org/10.1016/j.juro.2014.05.006>
- [3] Assimos, D., Krambeck, A., Miller, N.L., Monga, M., Murad, M.H., Nelson, C.P., *et al.* (2016) Surgical Management of Stones: American Urological Association/Endourological Society Guideline, PART I. *The Journal of Urology*, **196**, 1153-1160.

- <https://doi.org/10.1016/j.juro.2016.05.090>
- [4] Bai, Y., Tang, Y., Deng, L., Wang, X., Yang, Y., Wang, J., *et al.* (2017) Management of Large Renal Stones: Laparoscopic Pyelolithotomy versus Percutaneous Nephrolithotomy. *BMC Urology*, **17**, Article No. 75. <https://doi.org/10.1186/s12894-017-0266-7>
- [5] Wang, X., Li, S., Liu, T., Guo, Y. and Yang, Z. (2013) Laparoscopic Pyelolithotomy Compared to Percutaneous Nephrolithotomy as Surgical Management for Large Renal Pelvic Calculi: A Meta-Analysis. *The Journal of Urology*, **190**, 888-893. <https://doi.org/10.1016/j.juro.2013.02.092>
- [6] Mandhani, A. and Kapoor, R. (2009) Laparoscopic Ureterolithotomy for Lower Ureteric Stones: Steps to Make It a Simple Procedure. *Indian J Urol. Journal of the Urological Society of India*, **25**, 140-142. <https://doi.org/10.4103/0970-1591.45556>
- [7] Salvadó, J.A., Guzmán, S., Trucco, C.A. and Parra, C.A. (2009) Laparoscopic Pyelolithotomy: Optimizing Surgical Technique. *Journal of Endourology*, **23**, 575-578. <https://doi.org/10.1089/end.2008.0582>
- [8] Stein, R.J., Turna, B., Nguyen, M.M., Aron, M., Hafron, J.M., Gill, I.S., *et al.* (2008) Laparoscopic Pyeloplasty with Concomitant Pyelolithotomy: Technique and Outcomes. *Journal of Endourology*, **22**, 1251-1256. <https://doi.org/10.1089/end.2008.0003>
- [9] Meria, P., Milcent, S., Desgrandchamps, F., Mongiat-Artus, P., Duclos, J.M. and Teillac, P. (2005) Management of Pelvic Stones Larger than 20 mm: Laparoscopic Transperitoneal Pyelolithotomy or Percutaneous Nephrolithotomy? *Urologia Internationalis*, **75**, 322-326. <https://doi.org/10.1159/000089167>
- [10] Tiwari, K., Upadhaya, A.M., Kuwar, A. and Shrestha, S.B. (2019) Semi-Rigid Ureterscopy for the Management of Ureteric Calculi: Our Experience and Complication Encountered. *Journal of Nepal Health Research Council*, **17**, 233-237. <https://doi.org/10.33314/jnhrc.v0i0.1696>
- [11] Sahin, S., Resorlu, B., Atar, F.A., Eksi, M., Sener, N.C. and Tugcu, V. (2016) Laparoscopic Ureterolithotomy with Concomitant Pyelolithotomy Using Flexible Cystoscope. *The Journal of Urology*, **13**, 2833-2836.
- [12] Bokka, S. and Jain, A. (2019) Hounsfield Unit and Its Correlation with Spontaneous Expulsion of Lower Ureteric Stone. *Therapeutic Advances in Urology*, **11**. <https://doi.org/10.1177/1756287219887661>
- [13] Strobe, S.A., Wolf, J.S. and Hollenbeck, B.K. (2010) Changes in Gender Distribution of Urinary Stone Disease. *Urology*, **75**, 543-536. <https://doi.org/10.1016/j.urology.2009.08.007>
- [14] Şahin, S., Aras, B., Ekşi, M., Şener, N.C. and Tugçu, V. (2016) Laparoscopic Ureterolithotomy. *JSLs*, **20**, e2016.00004. <https://doi.org/10.4293/JSLs.2016.00004>
- [15] Shrestha, B., Karki, D.V. and Baidya, J.L. (2008) The Outcome of Pneumatic Lithotripsy for the Management of Ureteric Calculi. *Kathmandu University Medical Journal*, **6**, 355-360. <https://doi.org/10.3126/kumj.v6i3.1711>
- [16] Abedi, A.R., Razzaghi, M.R., Allameh, F., Aliakbari, F., FallahKarkan, M. and Ranjbar, A. (2018) Pneumatic Lithotripsy versus Laser Lithotripsy for Ureteral Stones. *Journal of Lasers in Medical Sciences*, **9**, 233-236. <https://doi.org/10.15171/jlms.2018.42>
- [17] Al-Sayyad, A. (2012) Laparoscopic Transperitoneal Ureterolithotomy for Large Ureteric Stones. *Urology Annals*, **4**, 34-37. <https://doi.org/10.4103/0974-7796.91619>
- [18] Bayar, G., Tanriverdi, O., Taskiran, M., Sariogullari, U., Acinikli, H., Abdullayev, E.,



*et al.* (2014) Comparison of Laparoscopic and Open Ureterolithotomy in Impacted and Very Large Ureteral Stones. *The Journal of Urology*, **11**, 1423-1428.

- [19] El-Feel, A., Abouel-Fettouh, H. and Abdel-Hakim, A.M. (2007) Laparoscopic Transperitoneal Ureterolithotomy. *Journal of Endourology*, **21**, 50-54.  
<https://doi.org/10.1089/end.2006.0141>