

# Complications of CAD/CAM Fabricated Surgical Template for Static Computer-Aided Implant Surgery

Yu Kishimoto<sup>1</sup>, Yuka Hasegawa<sup>1</sup>, Yasunori Kanemitsu<sup>1</sup>, Kuniteru Nagahara<sup>2</sup>, Tetsuji Nakamoto<sup>1\*</sup>

<sup>1</sup>Department of Maxillofacial Implant, Asahi University School of Dentistry, Mizuho, Japan

<sup>2</sup>Asahi University Medical and Dental Center, Mizuho, Japan

Email: \*tetsuji\_nakamoto@dent.asahi-u.ac.jp

**How to cite this paper:** Kishimoto, Y., Hasegawa, Y., Kanemitsu, Y., Nagahara, K. and Nakamoto, T. (2022) Complications of CAD/CAM Fabricated Surgical Template for Static Computer-Aided Implant Surgery. *Open Journal of Stomatology*, 12, 103-107. <https://doi.org/10.4236/ojst.2022.124010>

**Received:** February 24, 2022

**Accepted:** April 8, 2022

**Published:** April 11, 2022

Copyright © 2022 by author(s) and Scientific Research Publishing Inc. This work is licensed under the Creative Commons Attribution International License (CC BY 4.0). <http://creativecommons.org/licenses/by/4.0/>



Open Access

## Abstract

**Purpose:** Surgical templates produced by digital simulation and CAD/CAM allow for three-dimensional control of implant placement. However, due to clinical limitations, there are complications during the use of the template. The purpose of this study was to summarize the complications associated with the use of surgical templates for static computer-aided implant surgery. **Methods:** Complications were collected during the observation period, and then their implant sites were reanalyzed with simulation software. **Results:** There were 104 cases during the observation period, 5 cases had complications. Mechanical complications were observed in four cases, including three cases in which the frame of the template fractured during implant placement surgery and one case in which the sleeve fell off the surgical template. In one case, there was an error in the planned position. All cases were mandibular molar cases, and all cases of frame fracture were at the free end defect site. All cases had a Hounsfield unit of more than 700 at the implant site, and some of them had a significantly small jaw opening. **Conclusion:** Although the spread of CAD/CAM surgical templates has made it possible to avoid problems caused by the position of the implant, it has been difficult to avoid fractures in cases of mandibular free end defects with high Hounsfield unit.

## Keywords

CAD/CAM, Surgical Template, Static Computer-Aided Implant Surgery

## 1. Introduction

The use of a surgical template for implant placement has become common, but

with the development of digital technology, there has been a shift from relatively loose guidance using a finely tuned diagnostic template to full guidance using CAD/CAM processing that allows precise control of the depth of implant placement [1] [2] [3]. In recent years, dynamic navigation systems have begun to be introduced, and there have been many accuracy verifications. But in the current situation, coexistence with static navigation is essential due to the problem of equipment diffusion [4] [5]. Static navigation is generally produced by a 3D printer by superimposing scanner data and CBCT data and provides very strong guides. However, there are some clinical complications such as fractures during use and errors in placement. Therefore, the purpose of this study was to collect cases of problems with static navigation systems.

## 2. Materials and Methods

A total of 104 tooth-supported surgical templates used between July 2019 and May 2021 were validated with respect to complications during surgery. Surgical templates were fabricated using STL data from intraoral scanner impressions (TRIOS3: 3 Shape) and DICOM data from helical CT imaging superimposed on simulation software as full guides, except in cases with small mesio-distal distance (Nobel Guide or Straumann Guide). The implants were placed by two dentists with more than 10 years of experience. Photographs of the guides were taken after all problems occurred, and the causes of the problems were verified using simulation software (DTX Studio or coDiagnostiX).

## 3. Results

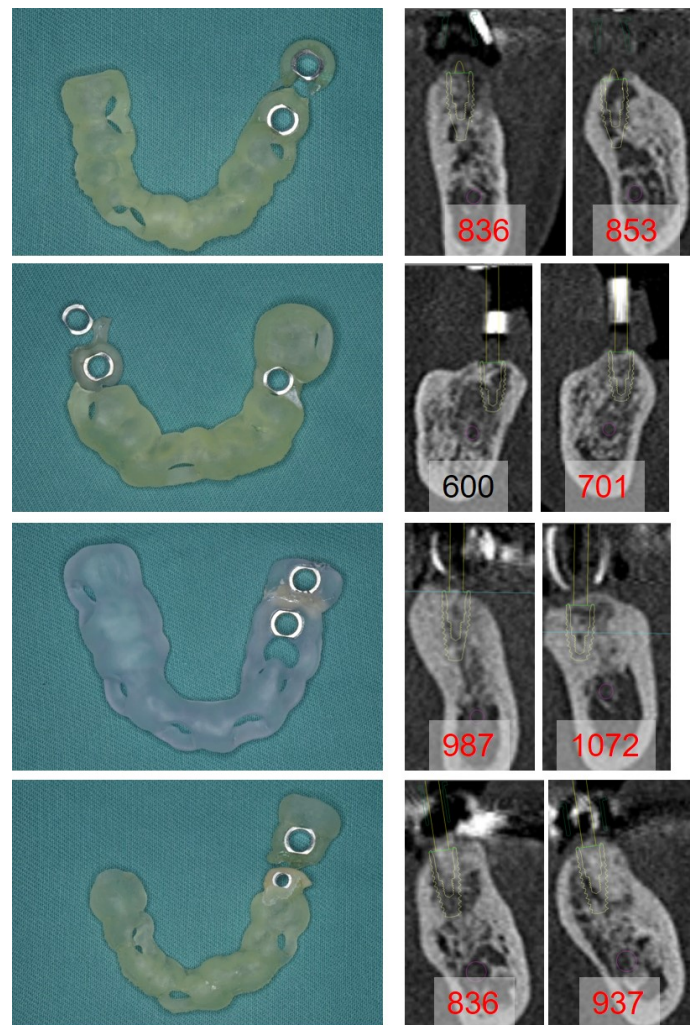
Of the 104 cases, 5 cases had complications caused by the surgical template. The implant placement surgery was not aborted because all fractures occurred after the formation of the smallest or second diameter drill. There were four mechanical complications (**Figure 1**), including three cases in which the frame of the surgical template fractured during implant placement and one case in which the sleeve fell off the surgical template. All four cases were mandibular molar placement cases.

In one case, there was a larger-than-expected error in the planned position (**Figure 2**). The positional error was approximately 2 mm buccal displacement. Since sufficient initial fixation was obtained in this case, the buccal-side defect was filled with carbonate apatite (Cytrans Granule, GC JAPAN), and a sufficient healing period was set.

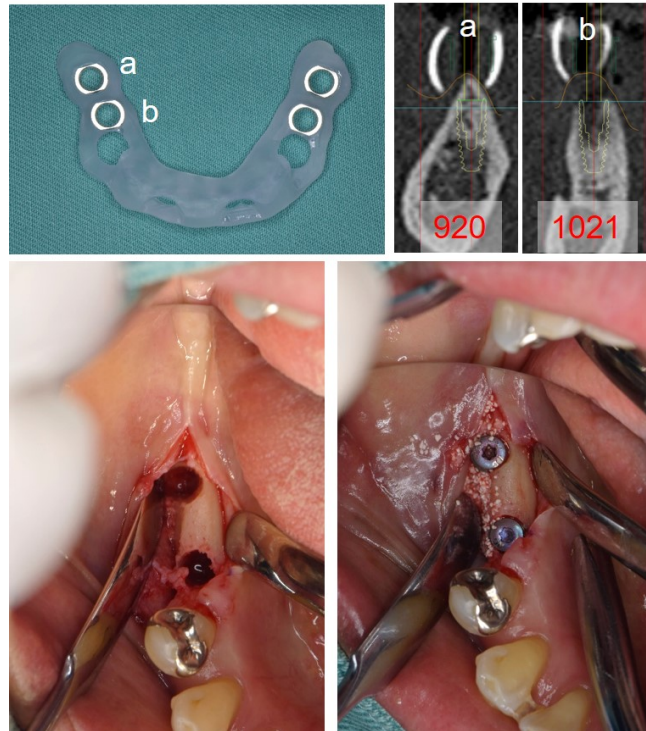
## 4. Discussion

The widespread use of 3D simulation software has made implant treatment safer, and the fabrication of surgical templates using 3D printers has further advanced this trend [1] [2]. However, it is difficult to insert the drill in molar cases where the opening is difficult to secure, so drill guides that slide in from the side as well as the vertical insertion direction have been developed. There is a study

that fabricates surgical templates with cobalt-chromium alloys, but it cannot be applied to all cases [6]. In recent years, 3D navigation has become commercially available as a method to eliminate these mechanical problems, and its widespread use may eliminate these mechanical problems. However, since it requires special equipment, it is likely that surgical templates made by 3D printers will continue to be the mainstream method for a while, considering its worldwide popularity. Therefore, in order to avoid this kind of mechanical problem, it is recommended to keep in mind that mechanical problems may occur in cases where the opening volume is small or the Hounsfield unit of the implant site exceeds 700.



**Figure 1.** Mechanical complications of static computer-aided implant surgery. Photographs of surgical template with mechanical complications during implant placement surgery (left panel) and CT image (right panel). The first to third rows show the cases surgical template body were broken. The fourth row is a case which the mesial sleeve fell off during surgery and then the template body was broken. The numbers on the CT image are the Hounsfield Unit around the implants calculated from the simulation software, and the values over 700 are shown in red.



**Figure 2.** A case of misalignment despite static computer-aided implant surgery. Surgical template (upper left) , CT images (upper right) and the recovery of the buccal V-shape bone defect (lower panels). Numbers on the CT images are the Hounsfield Unit around the simulated implants, and the values over 700 are shown in red.

Even if the surgical template is solidly made, the possibility of malposition should be kept in mind. In the case where malposition occurred, the implantation surgery was performed two weeks after the guide was completed, and the guide was stored in a light-shielded environment. Therefore, there were two possible causes of malpositioning: an error in the superimposition of DICOM and STL, and deflection of the surgical template during implantation because of the free edge defect. The bone quality at the site was also above 700. Therefore, caution may be necessary when the HU value is high due to mechanical problems and malpositioning. However, considering that CBCT is commonly used in the implant simulation process, it may be necessary to integrate the results of this study with the results of CBCT observation [7] [8].

### Acknowledgements

We thank Yuki Tanaka, Nanami Egawa, and Minori Matsuo for their technical assistance in carrying out this research. This work was supported by Miyata Research Grant.

### Conflicts of Interest

The authors declare no conflicts of interest regarding the publication of this paper.

## References

- [1] Joda, T., Derksen, W., Wittneben, J.G. and Kuehl, S. (2018) Static Computer-Aided Implant Surgery (s-CAIS) Analysing Patient-Reported Outcome Measures (PROMs), Economics and Surgical Complications: A Systematic Review. *Clinical Oral Implants Research*, **29**, 359-373. <https://doi.org/10.1111/clr.13136>
- [2] Vercruyssen, M., Laleman, I., Jacobs, R. and Quirynen, M. (2015) Computer-Supported Implant Planning and Guided Surgery: A Narrative Review. *Clinical Oral Implants Research*, **26**, 69-76. <https://doi.org/10.1111/clr.12638>
- [3] Van Assche, N., Vercruyssen, M., Coucke, W., Teughels, W., Jacobs, R. and Quirynen, M. (2012) Accuracy of Computer-Aided Implant Placement. *Clinical Oral Implants Research*, **23**, 112-123. <https://doi.org/10.1111/j.1600-0501.2012.02552.x>
- [4] Ramezanzade, S., Keyhan, S.O., Tuminelli, F.J., Fallahi, H.R., Yousefi, P. and Lopez-Lopez, J. (2021) Dynamic-Assisted Navigational System in Zygomatic Implant Surgery: A Qualitative and Quantitative Systematic Review of Current Clinical and Cadaver Studies. *Journal of Oral and Maxillofacial Surgery*, **79**, 799-812. <https://doi.org/10.1016/j.joms.2020.10.009>
- [5] Pozzi, A., Arcuri, L., Carosi, P., Nardi, A. and Kan, J. (2021) Clinical and Radiological Outcomes of Novel Digital Workflow and Dynamic Navigation for Single-Implant Immediate Loading in Aesthetic Zone: 1-year Prospective Case Series. *Clinical Oral Implants Research*, **32**, 1397-1410. <https://doi.org/10.1111/clr.13839>
- [6] Lin, W.S., Yang, C.C., Polido, W.D. and Morton, D. (2020) CAD-CAM Cobalt-Chromium Surgical Template for Static Computer-Aided Implant Surgery: A Dental Technique. *Journal of Prosthetic Dentistry*, **123**, 42-44. <https://doi.org/10.1016/j.prosdent.2019.04.014>
- [7] Gonzalez-Garcia, R. and Monje, F. (2013) The Reliability of Cone-Beam Computed Tomography to Assess Bone Density at Dental Implant Recipient Sites: A Histomorphometric Analysis by Micro-CT. *Clinical Oral Implants Research*, **24**, 871-879. <https://doi.org/10.1111/j.1600-0501.2011.02390.x>
- [8] Arisan, V., Karabuda, Z.C., Piskin, B. and Ozdemir, T. (2013) Conventional Multi-Slice Computed Tomography (CT) and Cone-Beam CT (CBCT) for Computer-Aided Implant Placement. Part II: Reliability of Mucosa-Supported Stereolithographic Guides. *Clinical Implant Dentistry and Related Research*, **15**, 907-917. <https://doi.org/10.1111/j.1708-8208.2011.00435.x>