

Facial and Orbital Emphysema after a Violent Nose-Blowing

Azeddine Lachkar*, Amine Salek, Drissia Benfadil, Fahd Elayoubi, Mohammed Rachid Ghailan

ENT and Head and Neck Surgery Department, University Hospital Center Mohammed VI, Faculty of Medicine and Pharmacy, Mohammed First University, Oujda, Morocco

Email: *drlachkar997@gmail.com

How to cite this paper: Lachkar, A., Salek, A., Benfadil, D., Elayoubi, F. and Ghailan, M.R. (2022) Facial and Orbital Emphysema after a Violent Nose-Blowing. *International Journal of Otolaryngology and Head & Neck Surgery*, 11, 107-111.
<https://doi.org/10.4236/ijohns.2022.113011>

Received: February 12, 2022

Accepted: May 13, 2022

Published: May 16, 2022

Copyright © 2022 by author(s) and Scientific Research Publishing Inc. This work is licensed under the Creative Commons Attribution International License (CC BY 4.0).

<http://creativecommons.org/licenses/by/4.0/>



Open Access

Abstract

Subcutaneous orbital and facial emphysema is a rare condition that may occur after a direct or indirect sinus trauma. A case report of a 25-year-old female complaining of bilateral swelling of the eyelid, orbital area, and facial puffiness, secondary to a violent nose-blowing. Computed tomography (CT) confirmed the diagnosis of subcutaneous emphysema. The initial treatment plan was puncture-suction and prophylactic intravenous antibiotic therapy. The patient was advised to not blow her nose. There has been no improvement in the patient's condition on the tenth day, so we performed a bilateral nasal packing by two Merocels (R), maintained for five days. After two weeks, the condition had completely resolved.

Keywords

Orbital Emphysema, Facial Emphysema, Nose-Blowing

1. Introduction

Facial and orbital emphysema is a rare condition that most of the time disappears spontaneously. It may occur after facial trauma, sinus surgery, or sinus barotrauma. This could be explained by a sinus defect. Except for these conditions, few scientific publications reported cases of orbital and facial emphysema. Few cases of orbital emphysema secondary to violent sneezing were reported. As well, some cases with no identifiable cause were defined as spontaneous emphysemas [1]. An exceptional case of spontaneous subcutaneous orbital and facial emphysema in a patient with no history of trauma or surgery is reported.

2. Case Report

A 25-year-old female patient with no history of trauma or sinus surgery, not re-

lating to any type of health-compromising, was admitted to the Otolaryngology department for bilateral swelling of upper eyelids and facial puffiness, secondary to a violent nose-blowing. Examination revealed bilateral ptosis with the incapacity of eye opening, and crepitus on palpation over the face and both eyelids (**Figure 1**). CT scan revealed facial subcutaneous emphysema extending to the eyelids and orbits, with no sign of ethmoiditis or orbital cellulitis, extensive sinus pneumatization, and defect on both lateral walls of the ethmoidal labyrinth (**Figure 2**). The patient underwent amoxicillin-clavulanic acid-based antibiotic treatment (1 g × 3/day) to minimize the risk of sinusitis and orbital cellulitis, and was advised to not blow her nose, as it can increase sinus pressure and worsens the emphysema. Ophthalmic examination finds normal visual acuity, with left ocular hypertension that required mannitol infusion. As well, we performed repeated needle aspiration at the upper eyelids. After ten days of hospitalization, there was no improvement. A bilateral nasal packing by two Merocels (R) maintained for five days was done. On day 15, the swelling was almost completely receded.

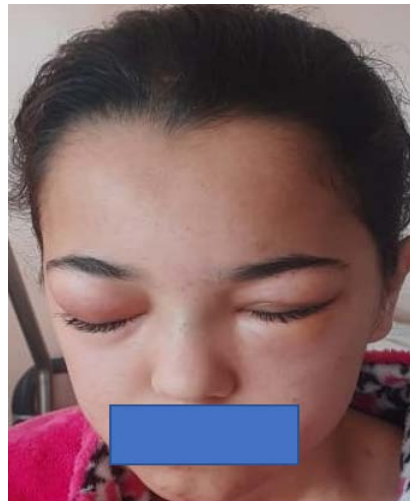

Figure 1. Facial and bilateral orbital emphysema.

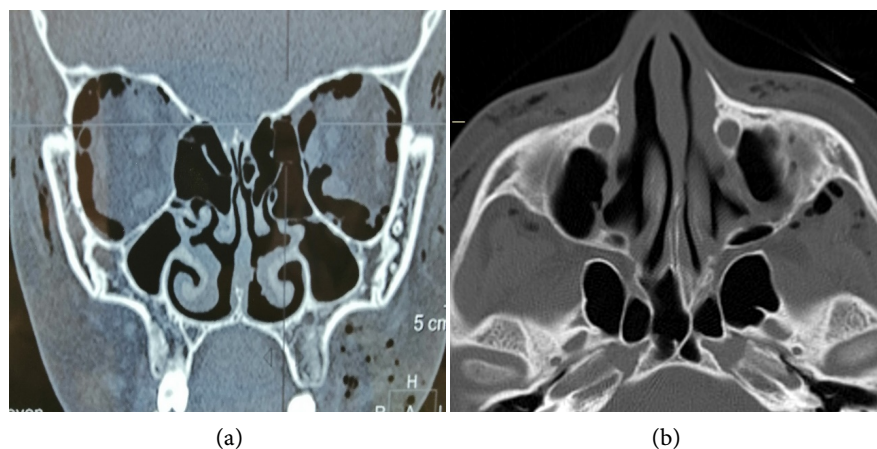


Figure 2. (a) Coronal CT scan showing orbital and facial emphysema; (b) axial CT scan revealing extensive sphenoid sinus pneumatization.

3. Discussion

Facial and orbital emphysema provides evidence of the defect in one or more of the sinus walls, in particular ethmoidal and frontal, and rarely sphenoidal. It happens after a facial trauma or sinus surgery [2]. Some cases of orbital emphysema after nose-blowing or violent sneezing are reported in patients with a history of trauma or sinus surgery [1] [3], which is not the case for our patients. Violent nose-blowing and sneezing increase the air pressure in the sinus cavity, which could create a defect in its area of weakness, particularly the lamina papyracea, especially in case of an important sinus pneumatization [4].

Facial and orbital emphysema with no history of facial trauma or sinus surgery is exceptional. Symptoms vary from person to person and depend on the severity of the emphysema. Patients complain of painful or non-painful abnormal ocular pressure. Sometimes, patients may present a decreased visual acuity, or diplopia, or both. Physical examination reveals crepitus on palpation of the face, especially in the infraorbital and frontal areas. Eyelid swelling causes often the impossibility of eye-opening. In severe cases, a proptosis or conjunctival emphysema could be observed [5]. The first-line investigation includes sinus computed tomography, which helps to make a positive diagnosis by showing air in the subcutaneous tissue of the face and the orbit, which can be intraconal or extraconal. CT scan helps also to make an aetiological diagnosis, by showing a defect, particularly in the lamina papyracea or the frontal sinus floor [6].

Pneumo-orbit could lead to visual acuity impairment and orbital cellulitis [7]. However, orbital cellulitis is an important differential diagnosis to consider, especially in febrile patients with hyperleukocytosis [8]. Moreover, in trauma cases, it is essential to exclude associated lesions that could be hidden by the extension of the emphysema into the retropharyngeal area or the mediastinum, hiding a possible associated oesophageal perforation. Finally, it is important to consider occult malignant tumours, particularly in persistent, recurrent or atypical cases [9].

In most cases, the emphysema resolves spontaneously and disappears usually in seven to ten days.

Conservative treatment is planned in the absence of ocular complications or cellulitis. Lamina papyracea fracture healing takes about 15 days, for this reason, nose-blowing, sneezing or coughing are not advised in this period [10]. Palpebral puncture is necessary to evacuate the air in order to reduce the globe's pressure. In case of failure, nasal packing is necessary, under the cover of antibiotics.

Surgical treatment is indicated in case of no improvement after a well-done conservative treatment. It consists of the closure of the defect of the lamina papyracea. Materials most used are abdominal fat, middle turbinate flap, septal cartilage flap, or fascia lata graft. The endoscopic approach is sufficient for the closure of most defects, except for lateral frontal sinus floor defects that require external approach surgery [11].

4. Conclusion

Facial and orbital emphysema secondary to nose-blowing is very rare. Initial management is guided by the severity of the emphysema. Conservative treatment is often sufficient. Computed tomography is essential for positive and aetiological diagnosis. The ignorance of this condition could lead to exorbitant diagnostic and therapeutic decisions.

Authors' Contributions

All the authors contributed to the conduct of this work.

Informed Consent

The informed consent was given by the patient.

Conflicts of Interest

The authors declare no conflict of interest.

References

- [1] Khader, Q.A. and Abdul-Baqi, K.J. (2010) Orbital Emphysema after a Protracted Episode of Sneezing in a Patient with No History of Trauma or Sinus Surgery. *Ear, Nose & Throat Journal*, **89**, 12-13. <https://doi.org/10.1177/014556131008901104>
- [2] Zimmer-Galler, I. and Bartley, G. (1994) Orbital Emphysema: Case Reports and Review of the Literature. *Mayo Clinic Proceedings*, **69**, 115-121. [https://doi.org/10.1016/S0025-6196\(12\)61036-2](https://doi.org/10.1016/S0025-6196(12)61036-2)
- [3] Li, T., Mafee, M.F. and Edward, D.P. (1999) Bilateral Orbital Emphysema from Compressed Air Injury. *American Journal of Ophthalmology*, **128**, 103-104. [https://doi.org/10.1016/S0002-9394\(99\)00037-9](https://doi.org/10.1016/S0002-9394(99)00037-9)
- [4] Roelofs, K.A., Starks, V. and Yoon, M.K. (2019) Orbital Emphysema: A Case Report and Comprehensive Review of the Literature. *Ophthalmic Plastic & Reconstructive Surgery*, **35**, 1-6. <https://doi.org/10.1097/IOP.0000000000001216>
- [5] Hatton, M.P. and Rubin, P.A. (2007) Management of Orbital Compartment Syndrome. *Archives of Ophthalmology*, **125**, 433-434. <https://doi.org/10.1001/archophth.125.3.433-b>
- [6] Alimehmeti, R., Gjika, A. and Kruja, J. (2011) Orbital Emphysema after Nose Blowing. *Neurology*, **76**, Article No. 1274. <https://doi.org/10.1212/WNL.0b013e3182143523>
- [7] Zachariades, N. and Mezitis, M. (1988) Emphysema and Similar Situations in and around the Maxillo-Facial Region. *Revue de Stomatologie et de Chirurgie Maxillo-faciale*, **89**, 375-379.
- [8] Cheema, R.A., Lukaris, A.D. and Lane, C.M. (2000) Orbital Cellulitis with Gas. *Orbit*, **19**, 41-44. [https://doi.org/10.1076/0167-6830\(200003\)19:1:1-Z;FT041](https://doi.org/10.1076/0167-6830(200003)19:1:1-Z;FT041)
- [9] Ong, W.C., Lim, T.C., Lim, J., et al. (2005) Cervicofacial, Retropharyngeal and Mediastinal Emphysema: A Complication of Orbital Fracture. *Asian Journal of Surgery*, **28**, 305-308. [https://doi.org/10.1016/S1015-9584\(09\)60367-5](https://doi.org/10.1016/S1015-9584(09)60367-5)
- [10] Seiff, S.R. (2002) Perspective: Atmospheric Pressure Changes and the Orbit: Recommendations for Patients after Orbital Trauma or Surgery. *Ophthalmic Plastic &*

Reconstructive Surgery, **18**, 239-241.

<https://doi.org/10.1097/00002341-200207000-00001>

- [11] Furlani, B.A., Diniz, B., Bitelli, L.G., et al. (2009) Sight-Threatening Orbital Emphysema after Nose Blowing: Case Report. *Arquivos Brasileiros de Oftalmologia*, **72**, 251-253. (In Portuguese) <https://doi.org/10.1590/S0004-27492009000200024>